



DIVINE GRANULOMAS-MYSTERY UNFOLDED

Leena Dennis Joseph, R Sowndharya, L Somu* Department of Pathology & Department of ENT*
Sri Ramachandra Institute of Higher Education and Research, Chennai

POSTER ID: 52

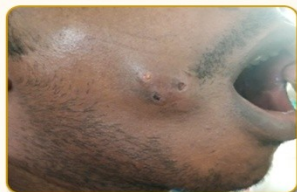BACKGROUND

- In India, majorly in the southern states piercings of metal spears and hooks, kavadi (wood steel bearings with idols) on the cheeks, tongue, chest or back is a common ritual done during tamil month of Thai.
- This leads to the rare occurrence of sarcoidal granulomatous reaction developing at the sites of piercings.

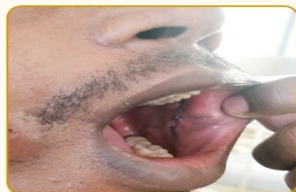
CASE DETAILS

- 26 year old male patient
- multiple swellings over the face and mucous areas of the mouth progressively enlarging in size and painful
- Similar lesions were present on chest wall and back for the past 3 months
- Detailed history revealed piercing with metal spears through his cheeks and torso during "Thai pusam" a few months
- Smearing of the holy ash on to the spears and hooks before they were pierced
- Physical examination - multiple nodules on both sides of his cheeks, chest and back, approximately 2 cms in size, firm
- Biopsy revealed multiple, naked non caseating granulomas with numerous foreign body type of giant cells. Stains for the fungus and AFB were negative.
- A diagnosis of cutaneous sarcoidosis was given.

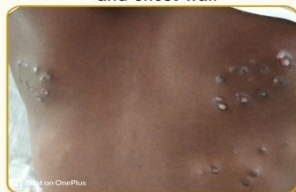The lesion on the cheeks



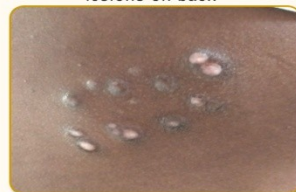The intramucosal lesion



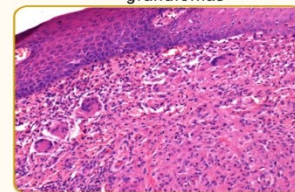
Lesions over the back and chest wall



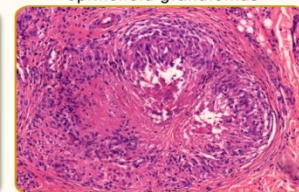
Closer magnification of the lesions on back



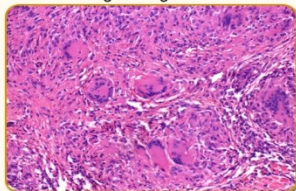
Skin with dermis showing granulomas



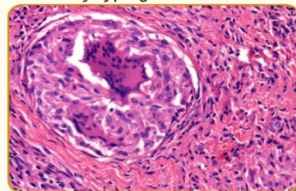
Dermis showing a naked epithelioid granulomas



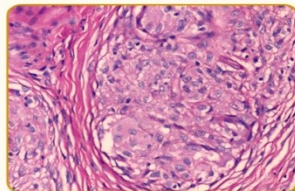
Granulomas with many langhans giant cells



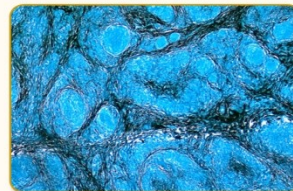
Granuloma with a foreign body type giant cell



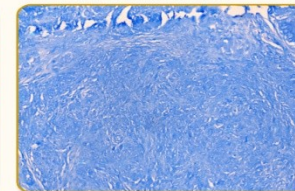
Naked granuloma



GMS stain



Negative AFB stain



FOREIGN MATERIAL PRODUCING SARCOIDAL GRANULOMAS

Silica (including windshield glass)
Silicone
Tattoo pigments
Zirconium

Beryllium
Zinc
Acrylic or nylon fibers
Keratin from ruptured cysts (uncommon)

Exogenous ochronosis
Sea-urchin spines
Cactus
Wheat stubble

Desensitizing injections
Ophthalmic drops (sodium bisulfite)
Sulfonamides
Interferon injection sites

DISCUSSION

Dermal infiltrate of naked sarcoidal granulomas
Increased mucin is (20% of cases)
Asteroid bodies and conchoidal bodies (Schaumann bodies) may be seen in multinucleate giant cells

TYPES OF GRANULOMAS

Sarcoidal
Tuberculous
Necrobiotic
(collagenolytic)
Suppurative

Foreign body
Xanthogranulomas
Miscellaneous